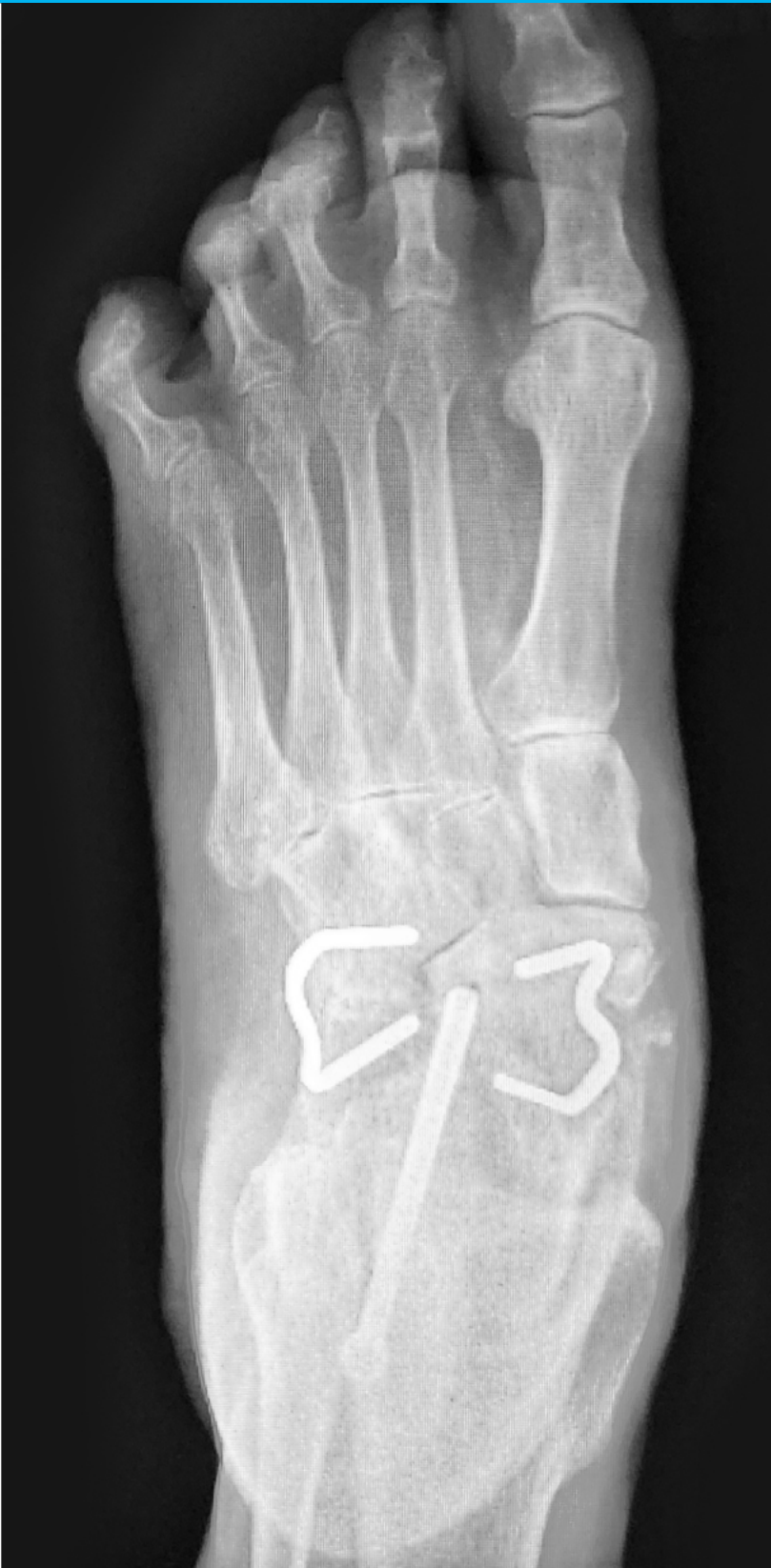
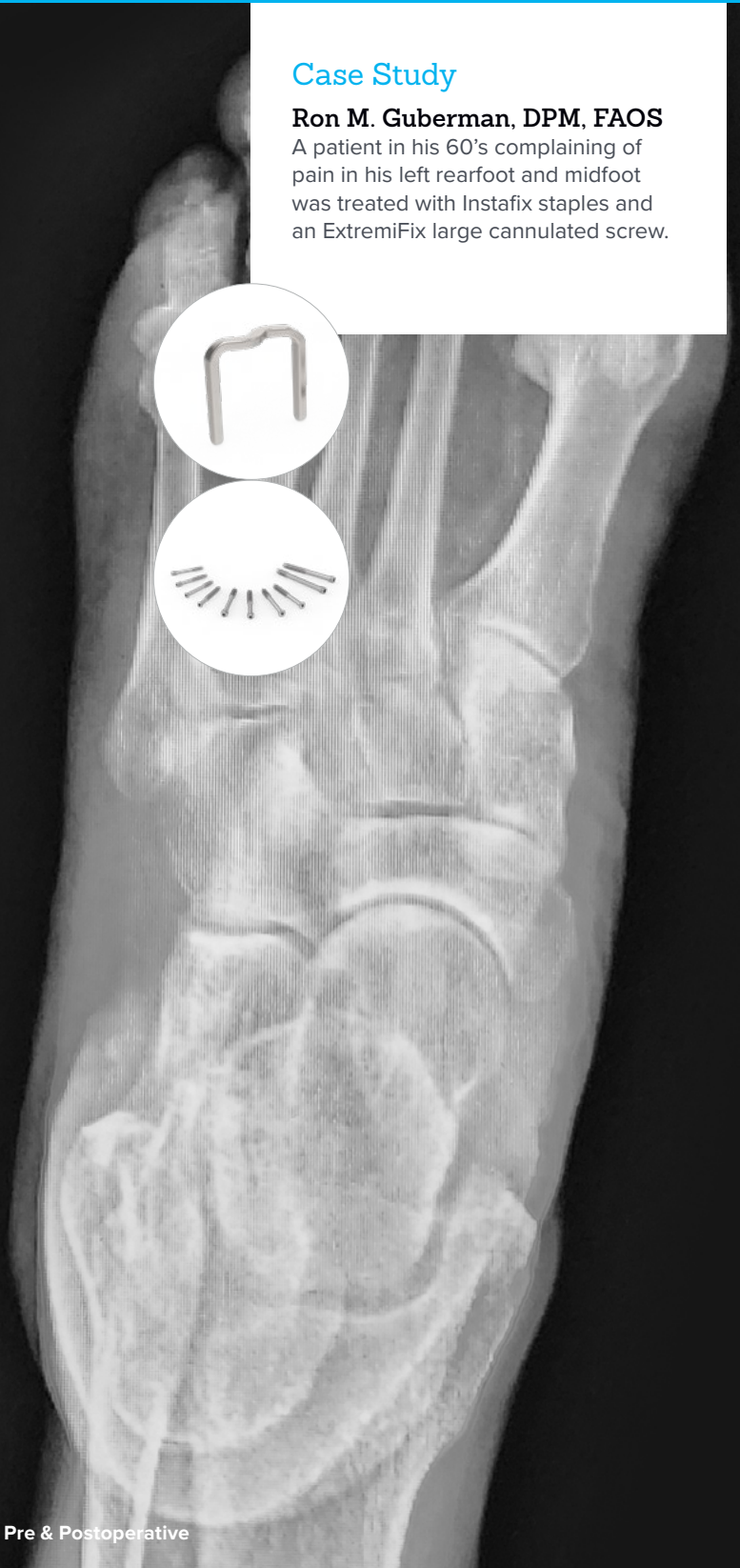

## Flatfoot Deformity - Progressive Collapsing Foot Deformity

### Case Study

**Ron M. Guberman, DPM, FAOS**

A patient in his 60's complaining of pain in his left rearfoot and midfoot was treated with Instafix staples and an ExtremiFix large cannulated screw.

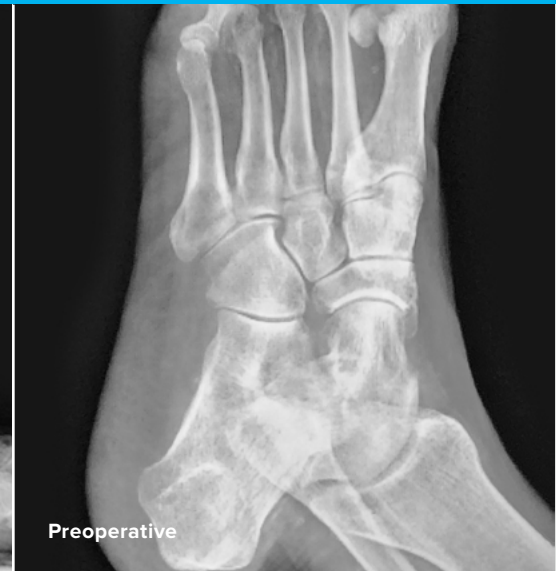
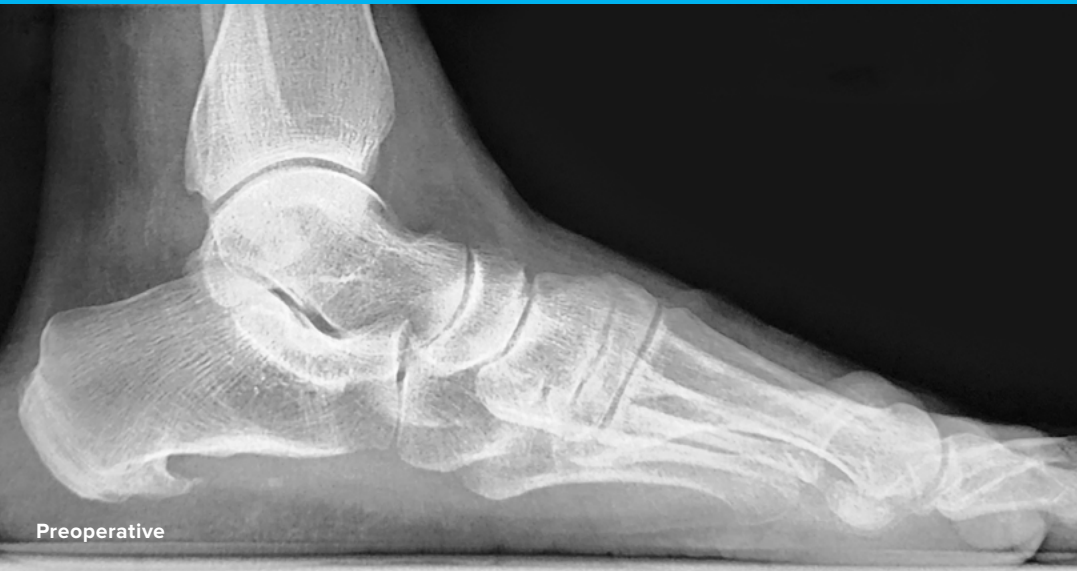
Acumed® is a global leader of innovative orthopaedic and medical solutions.



We are dedicated to developing products, service methods, and approaches that improve patient care.

## Case Study



**Ron M. Guberman, DPM, FAOS**  
Wyckoff Heights Medical Center

## Flatfoot Deformity - Progressive Collapsing Foot Deformity

### Patient History

A patient in his 60s had been complaining of rearfoot and midfoot pain for a considerable time. He was given custom foot orthoses, physical therapy, and NSAIDs. He had moderate flatfoot deformity, that is now described as Progressive collapsing foot deformity.

## Treatment

In some cases, there are more serious technical challenges based on the physical, structural, and biomechanical presentation. In this case, the greatest challenge was delivering a high-quality result. This patient was a police detective and demanded quality care and results. So, delivering an excellent result clinically, radiographically, and functionally was of utmost importance.

We performed a triple arthrodesis, that was successful. The goals of the surgery were to provide pain-free and function triple arthrodesis for an older but very active person. He likes to walk a lot and has a special-needs son he takes care of. Despite the use of various custom orthoses and modifications, and consults with other specialists, we were unable to get the patient to a point where he could be pain-free and function without surgery.

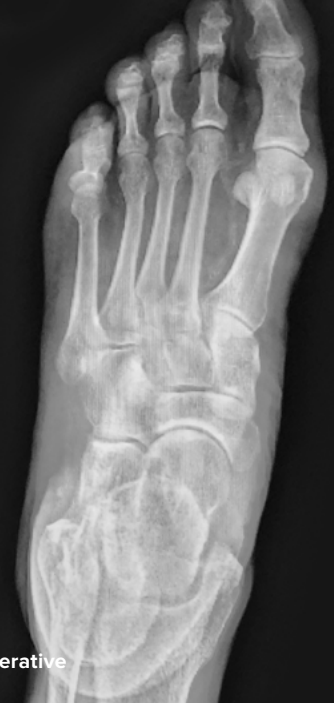I chose to perform triple arthrodesis because trying a double or STJ fusion seemed riskier. The patient had significant pain and arthritic symptoms in the subtalar, TN and C-C joints. There appeared to be no other viable option. Trying anything less than a triple arthrodesis, would likely result in continued symptoms in the medial and lateral columns.

In cases like this where there is not any extreme angular deformity on any plane, I perform the subtalar, then TN, then CC joint prep, and fixate in that order. Once I have the STJ fixated temporarily I can then easily visualize the TN and the CC for apposition and apply bone graft as needed. I used a small incision for the STJ to access the posterior facet with adequate visualization, about 3.5 cm long. After careful dissection to expose the joint, I used small osteotomes and a small rongeur to remove the cartilage to bleeding subchondral bone to minimize bone resection. I also used this technique for the TN joint. The position of his foot was already a slight valgus, so minimal to no angular correction was required.

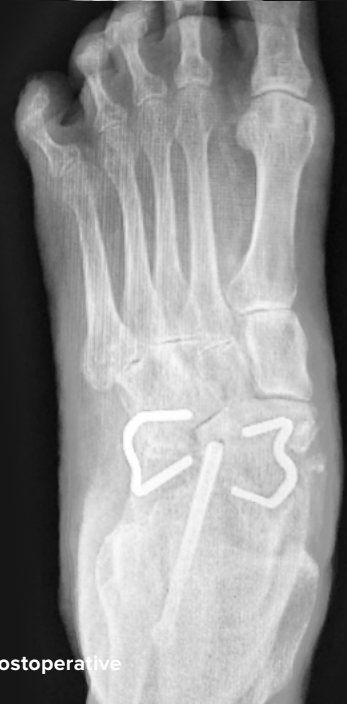Next, I performed a dorsomedial incision for the TN joint. I prefer the incision more dorsal than the standard because it gives me better visualization of the entire joint and easily allows contoured removal of the cartilage. The medial incision makes it more difficult to see and access the later joint due to curvature of the joint. After removing the cartilage to bleeding subchondral bone, I then made a lateral linear incision over the CC joint and exposed and resected the joint with a sagittal saw. Careful inspection and work in resection of all joints is critical, but especially for the STJ and TN. I added some bone graft and DBM putty prior to temporary fixate the STJ and ensured the alignment of the ankle and forefoot were considered before inserting the Steinman pin with a slight valgus attitude. Once I had intraop films AP lat and calc axial, I then proceeded to evaluate the TN and CC, positioning the forefoot also in slight valgus and abduction and plantigrade. I then added DBM putty and some bone chips to both the TN side, which I fixed with a Steinman pin, followed by the CC. Intraop fluoroscopy confirmed desired alignment and I used a single screw for the STJ since this seemed to hold well and the fixation was strong and in good position. I will use a second screw if needed, but not in this case. I will generally use staples around 20 mm in width and with 20 to 25 leg length for the TN and CC as I did in this case, because it is easy and supplies good compression. I will sometimes use a second staple for the TN if I feel additional compression is needed, but the alignment and position were satisfactory in this case with one.

## Postoperative Care

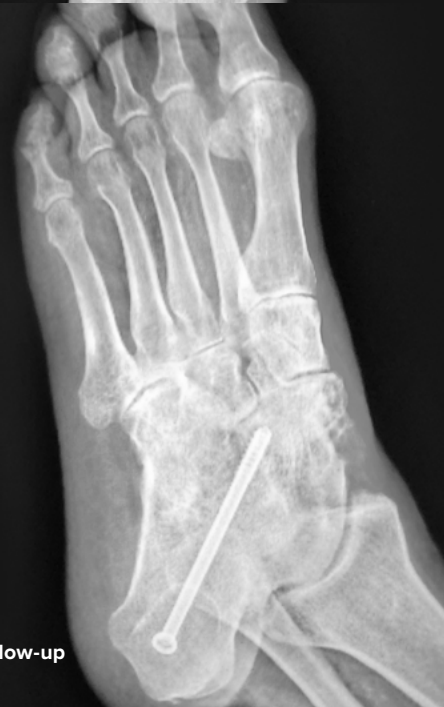Later, we removed the staples where there was either actual or perceived pain from this hardware. To date, over four years after the surgery, the fusions have been successful in stabilizing the deformity, allowing for good function and greatly reducing the pain. The patient is very satisfied with the outcome.



Preoperative



Postoperative



Follow-up



## **FNA70-16-A**

Effective: 2023/10

© 2023 Acumed® LLC

[www.acumed.net](http://www.acumed.net)

Acumed USA Campus  
5885 NE Cornelius Pass Road  
Hillsboro, OR 97124  
+1.888.627.9957

OsteoMed USA Campus  
3885 Arapaho Road  
Addison, TX 75001  
+1.800.456.7779

Acumed Iberica Campus  
C. Proción, 1  
Edificio Oficor  
28023 Madrid, Spain  
+34.913.51.63.57

These materials contain information about products that may or may not be available in any particular country or may be available under different trademarks in different countries. The products may be approved or cleared by governmental regulatory organizations for sale or use with different indications or restrictions in different countries. Products may not be approved for use in all countries. Nothing contained on these materials should be construed as a promotion or solicitation for any product or for the use of any product in a particular way which is not authorized under the laws and regulations of the country where the reader is located. Specific questions physicians may have about the availability and use of the products described on these materials should be directed to their particular authorized Acumed distributor. Specific questions patients may have about the use of the products described in these materials or the appropriateness for their own conditions should be directed to their own physician.

OsteoMed LLC is a wholly owned subsidiary of Acumed LLC. OsteoMed®, ExtremiFix™, and Instafix™ are registered trademarks of OsteoMed LLC. Acumed® is a registered trademark of Acumed LLC.

a Colson Medical | Marmon | Berkshire Hathaway Company

