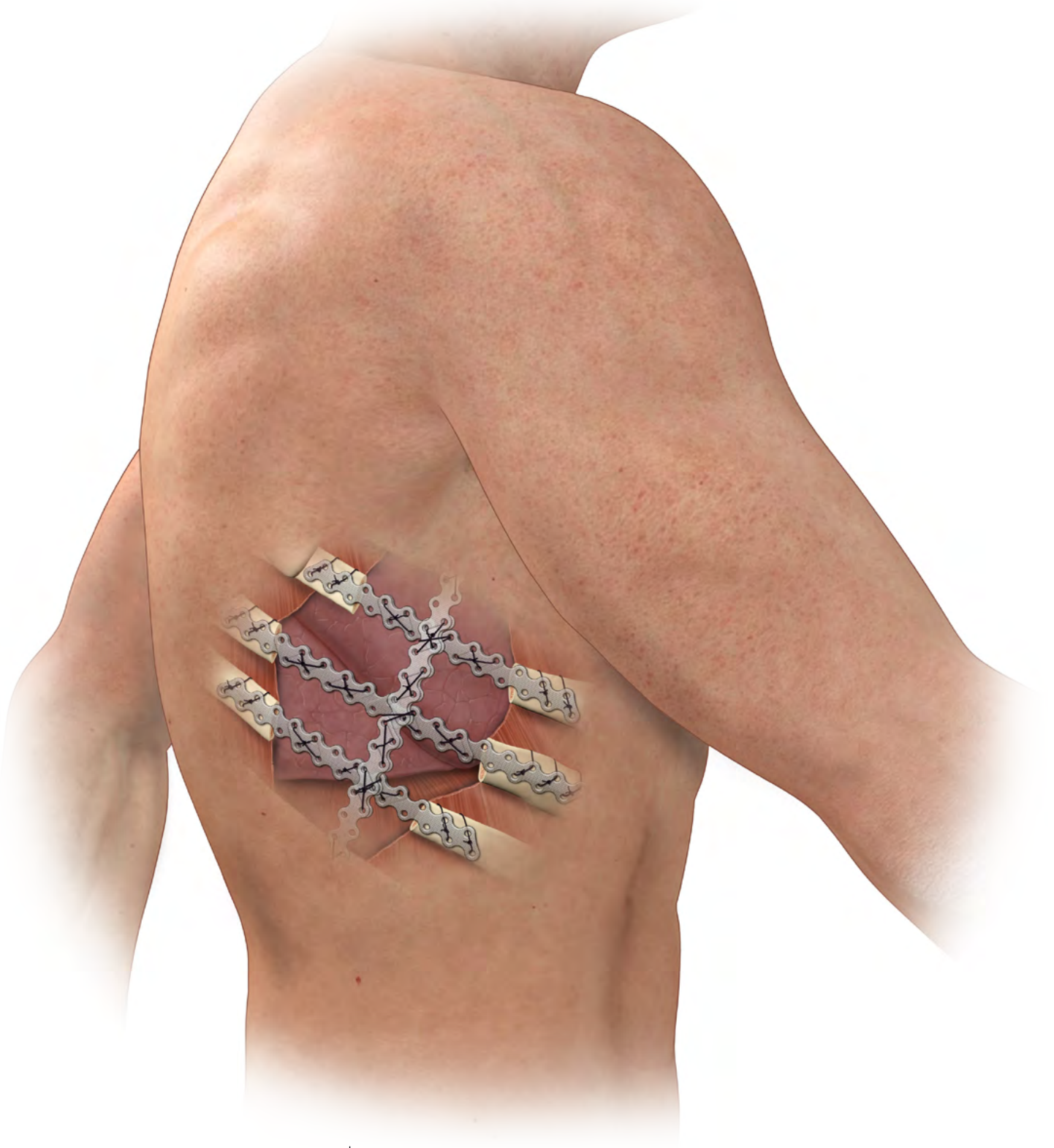


BioBridge®

Resorbable Chest Wall Stabilization Plate
Chest Wall Reconstruction

Surgical Technique



Chest Wall Reconstruction

Statement from Acute Innovations: The goal of this monograph is to describe a novel technique for chest wall reconstruction after resection using biomaterials.

Reconstruction may be indicated due to chest wall tumors (benign and malignant), radiation necrosis, contiguous lung or breast cancer, and lung/chest wall infections^{4,7} and trauma. This reconstruction technique provides long-term chest wall stability through bone healing and/or soft tissue scarring.

This document is intended for support and educational purposes and is not to be used in any other capacity. All questions regarding surgical implantation of the product should be directed to a licensed medical professional familiar with Acute Innovations products. In addition, consult the product's 'Instructions for Use' for more detailed information.



Daniel Miller, MD

Chief, General Thoracic Surgery
CTCA (Cancer Treatment Centers of America, Atlanta) Atlanta, GA

Overview

Clinical Summary of Chest Wall Resections

Indication for chest wall resection can include chest wall tumors (benign and malignant), radiation necrosis, contiguous lung or breast cancer, and lung/chest wall infections.^{4,7} The locations of resections vary, but have been shown to occur more commonly in ribs than the sternum (Table 1).

Resection Location	Rate
Anterior Ribs	33%
Anterolateral Ribs	20%
Lateral Ribs	19%
Posterior Ribs	13%
Posterolateral Ribs	13%
Sternum – Upper	8%
Sternum – Mid	2%
Sternum – Lower	2%

Table 1: Summary of resection location in 200-patient study (Mansour et al.)⁶

Mansour et al. summarized the optimal chest wall resection and reconstruction as having 3 tenets:

- ▶ Sufficient amount of tissue must be resected to remove all devitalized tissue.
- ▶ In large chest wall resections, chest wall replacement must be performed to restore the rigid chest wall to prevent physiologic flail.
- ▶ Healthy soft-tissue coverage is essential to seal the pleural space, to protect the thoracic viscera and great vessels, and to prevent infection.

When chest wall dynamics are not compromised (i.e., no flail chest), reconstruction may not be required.³ However, even when chest wall continuity is maintained, reconstruction may be desired to enhance cosmesis and protect underlying structures.^{6,7,9}

When chest wall dynamics are compromised, reconstruction to restore chest wall rigidity is often recommended.^{1,3-4, 6-9}

In a review of 101 chest wall reconstruction cases comparing autogenous and prosthetic repair (i.e., mesh), it was noted that ventilator use was 5 times more frequent in patients who had autogenous reconstruction alone. Hospital stay was also prolonged for these patients.⁵

Guidelines for Reconstruction

A 3D reconstruction CT scan is used to determine the size, location, and extent of the resection and reconstruction that is needed for each patient. The reconstruction method depends primarily on location and size of the resection. For example, smaller resections (<5 cm) or resections under the scapula (ribs 1–3) usually do not require reconstruction.

Larger or more anterior chest wall defects are more likely to require material implants to prevent lung herniation or flail chest, and to restore a natural cosmetic shape.

Reconstruction Technique

The technique described here is preferred for three primary benefits:

- ▶ The BioBridge plate provides a dynamic support for reconstruction.
- ▶ Bovine pericardium maintains a watertight seal of the chest and provides a scaffold for tissue ingrowth.
- ▶ The reconstruction material absorbs, remodels, and is replaced by normal soft tissue.

To start, all devitalized tissue is removed. In cases of malignant tumor removal, it is recommended that, at minimum, an additional 4 cm margin grossly free of the tumor be resected.¹

Preparation of BioBridge Plates

Prepare for the reconstruction by measuring the chest wall defect. When planning the length of the plate, measure the distance between the planned anchor ribs bilaterally and account for at least 4 holes (1 cm) overlap with the rib at each anchor point. Use a non-absorbable suture no smaller than a USP size 2.

If the defect is larger than 8 cm, BioBridge plates can be stacked in either a “doublet” or “triplet” configuration and sutured together to form one long stabilizer. When stacking, overlap at least 4 holes and ensure each overlapping hole is sutured together, then add suture around the scallops in the plate to ensure a rigid construct (Figure 1).

Important: The stacked stabilizer must be rigid. If the final construct is loose, remove any loose sutures and re-tie them. Add BioBridge plates if additional stiffness is necessary.




Figure 1: BioBridge doublet and triplet

- ▶ Two stacked plates (doublet) sutured together to form one longer stabilizer, minimum 8-hole overlap (12-hole overlap shown here).
- ▶ Suture through the holes and around the scallops of the plates in order to achieve a tight stabilizer construct.

Reconstruction Technique [continued]

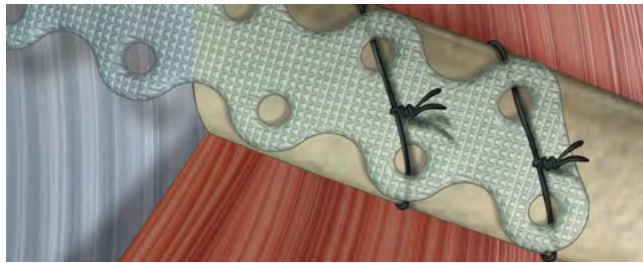


Figure 2: Minimum of two sutures at each anchoring point

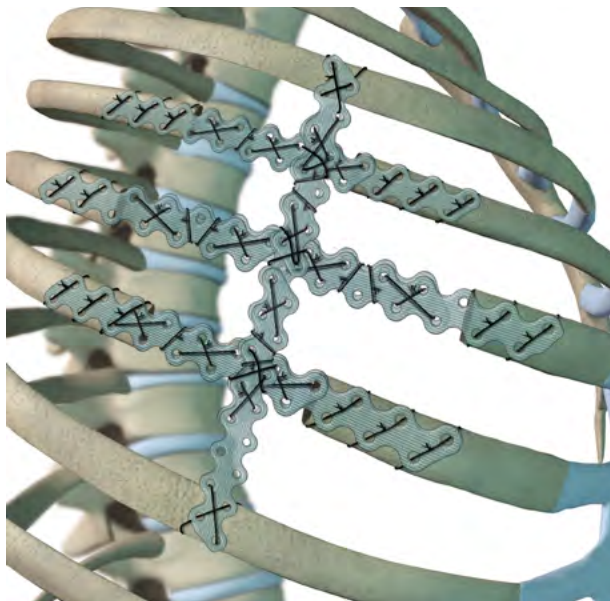


Figure 3: Reconstruction of resection site

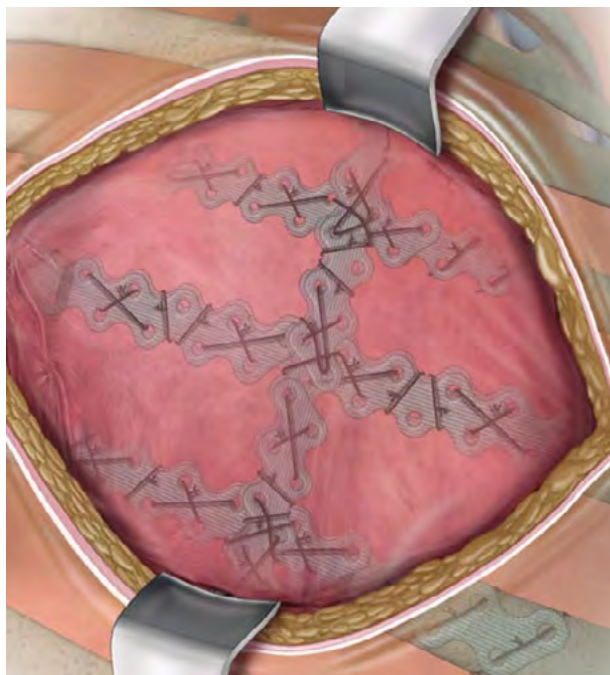


Figure 4: Pericardial patch is secured in place

Installation

Anchor each end of the plate or stabilizer with at least two sutures running through the top and bottom holes of the BioBridge and around the rib (Figure 2). Alternatively, suture may be passed through the ribs. An example of a bioresorbable reconstruction using BioBridge is shown in Figure 3. In this case, each resected rib is bridged and a perpendicular BioBridge triplet is used to add stability.

Note: In very large resections involving multiple rib levels, a more rigid construct may be needed in place of the resorbable plates (i.e., metal struts or a methyl methacrylate sandwich).

Once the desired reconstruction is achieved, the bovine pericardium is stretched over the defect and sutured to the chest wall muscle and ribs. The pericardial patch is tightened, like a drum, creating a seal and preventing paradoxical motion of the chest wall (Figure 4).

In the case of a full-thickness (including soft tissue) chest wall reconstruction, a muscle flap is preferred to provide viable tissue to cover the reconstruction material and prevent infection. Table 2 contains types of muscle flaps used in chest wall reconstruction and associated frequencies of use. A plastic surgeon should be consulted when a muscle flap may be necessary for reconstruction.

Reconstruction Technique [continued]

Autogenous Tissue Replacement	Rate
Pedicle Flap	48%
Free Flap	9%
Latissimus Muscle	20%
TRAM	17%
Pectoralis Muscle	16%
Serratus Muscle	9%
Deltoid Muscle	2%
Trapezius Muscle	2%
Omentum	10%
STSG	12%

Table 2: Muscle flap type and frequency (Mansour et al)⁶

Complications	Rate
Respiratory	24%
Seroma	7%
Wound Infection	5%
Arrhythmia	3%
Hemorrhage	2%
Myocardial Infarction	2%
Prolonged Air Leak	1%
Other	3%

Table 3: Complications reported from chest wall reconstruction³

Closure and Follow Up

Following chest wall reconstruction, pain management is typically achieved with an epidural catheter. Jackson-Pratt (JP) drains are usually used above the reconstruction material to prevent seromas. When fluid drainage is less than 50 cc in a 24-hour period, the drain is removed. Some patients may be sent home with a JP drain. Pain medications are typically needed 4–6 weeks postoperative. Patients should limit lifting over 20 lb and additional restrictions may be needed if muscle flaps are used.

Complications

Complications relating to chest wall resection and reconstruction can be significant and should be understood before performing the resection. Deschamps et al. found that 46% of patients experienced complications. A summary of complications related to chest wall reconstruction is provided in Table 3. Note that these complications are not specific to the method discussed here.

Conclusion

Chest wall reconstructions are complex procedures requiring individualized solutions and an experienced team. The use of biomaterials such as the BioBridge plate and bovine pericardium, and free, or pedicled muscle flaps, offers a distinctive solution that is dynamic and customizable. This technique can provide long-term stability, a dynamic, watertight seal, and a restored chest wall at the site of the defect that allows for the eventual incorporation of normal tissue.

Appendix

For additional information on the BioBridge Resorbable Chest Wall Stabilization Plate, contact your local Acute Innovations sales representative or visit www.acuteinnovations.com.

BioBridge Plate Indications

In the presence of appropriate additional immobilization or fixation, indicated for maintaining the alignment and fixation of bone fractures, osteotomies, arthrodeses, or bone grafts, and maintenance of relative position of weak bony tissue (e.g., bone grafts, bone graft substitutes, or bone fragments from comminuted fractures), in trauma and reconstructive procedures.

Specific indications:

- ▶ Metacarpus, proximal and middle phalangeal bones
- ▶ Long bones, flat bones, short bones, irregular bones, appendicular skeleton, and thorax



References

1. Athanassiadi K, Kalavrouziotis G, Rondogianni D, Loutsidis A, Hatzimichalis A, Bellenis I. Primary chest wall tumors: early and long-term results of surgical treatment. *Eur J Cardiothorac Surg*. 2001 May; 19(5): 589-593.
2. Coonar AS, Qureshi N, Smith I, Wells FC, Reisberg E, Wihlm JM. A novel titanium rib bridge system for chest wall reconstruction. *Ann Thorac Surg*. 2009 May; 87(5): e46-48.
3. Deschamps C, Tirnaksiz BM, Darbandi R, Trastek VF, Allen MS, Miller DL, Arnold PG, Pairolero PC. Early and long-term results of prosthetic chest wall reconstruction. *J Thorac Cardiovasc Surg*. 1999 Mar; 117(3): 588-591; discussion 591-592.
4. Downey RJ, Rusch V, Hsu FI, Leon L, Venkatraman E, Linehan D, Bains M, van Zee K, Korst R, Ginsberg R. Chest wall resection for locally recurrent breast cancer: is it worthwhile? *J Thorac Cardiovasc Surg*. 2000 Mar; 119(3): 420-428.
5. Kroll SS, Walsh G, Ryan B, King RC. Risks and benefits of using Marlex mesh in chest wall reconstruction. *Ann Plast Surg*. 1993 Oct; 31(4): 303-306.
6. Mansour KA, Thourani VH, Losken A, Reeves JG, Miller JI Jr, Carlson GW, Jones GE. Chest wall resections and reconstruction: a 25-year experience. *Ann Thorac Surg*. 2002 Jun; 73(6): 1720-1725; discussion 1725-1726.
7. Martini N, Huvos AG, Burt ME, Heelan RT, Bains MS, McCormack PM, Rusch VW, Weber M, Downey RJ, Ginsberg RJ. Predictors of survival in malignant tumors of the sternum. *J Thorac Cardiovasc Surg*. 1996 Jan; 111(1): 96-105; discussion 105-106.
8. Miller D., Force S., Pickens A., Fernandez F., Luu T., Mansour K. Chest wall reconstruction using biomaterials. *Ann Thorac Surg*. 2013, 95(3); 1050-1056.
9. Soysal O, Walsh GL, Nesbitt JC, McMurtrey MJ, Roth JA, Putnam JB Jr. Resection of sternal tumors: extent, reconstruction, and survival. *Ann Thorac Surg*. 1995 Nov; 60(5): 1353-1358; discussion 1358-1359.



Acumed Headquarters
5885 NE Cornelius Pass Road
Hillsboro, OR 97124
Office: +1.888.627.9957
Office: +1.503.627.9957
Fax: +1.503.520.9618
www.acuteinnovations.com

Back to health. Back to work. Back to **life.**

RRP7120-D | Effective: 2020/12 | © 2020 Acumed® LLC

These materials contain information about products that may or may not be available in any particular country or may be available under different trademarks in different countries. The products may be approved or cleared by governmental regulatory organizations for sale or use with different indications or restrictions in different countries. Products may not be approved for use in all countries. Nothing contained in these materials should be construed as a promotion or solicitation for any product or for the use of any product in a particular way that is not authorized under the laws and regulations of the country where the reader is located. Nothing in these materials should be construed as a representation or warranty as to the efficacy or quality of any product, nor the appropriateness of any product to treat any specific condition. Physicians may direct questions about the availability and use of the products described in these materials to their authorized Acumed distributor. Specific questions patients may have about the use of the products described in these materials or the appropriateness for their own conditions should be directed to their own physician.

Not all products may currently be available in all markets.

Please also refer to the package insert(s) or other labeling associated with the devices identified in this reference guide for additional information.