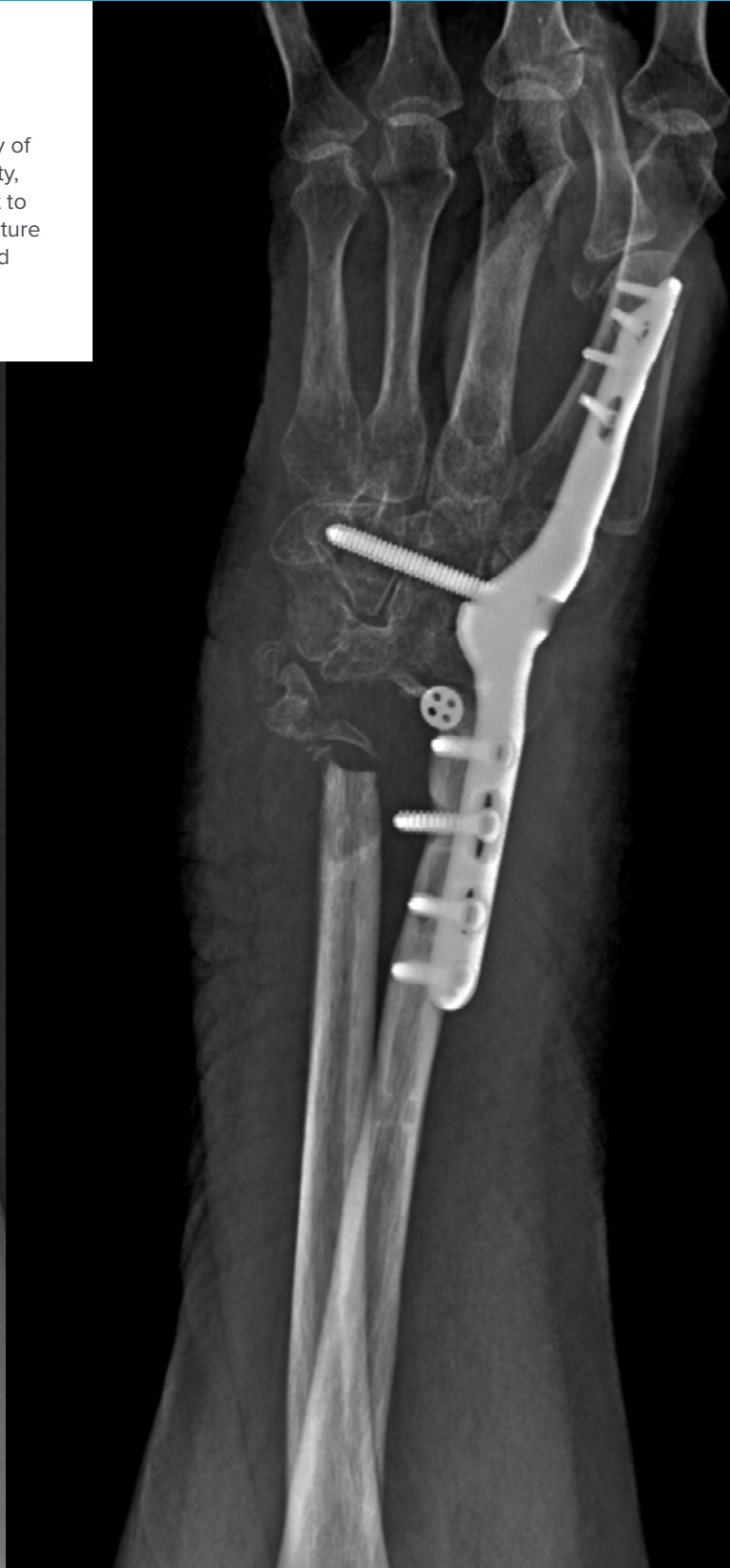
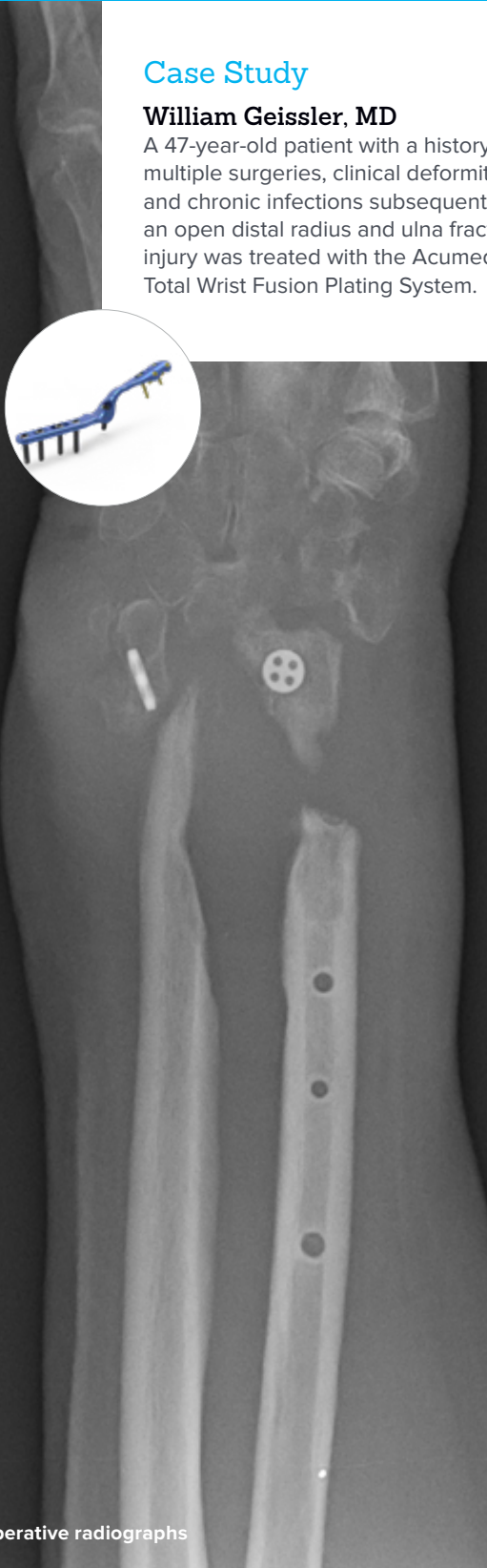
Wrist Salvage Procedure Using Second Metacarpal Plate Placement

Case Study

William Geissler, MD

A 47-year-old patient with a history of multiple surgeries, clinical deformity, and chronic infections subsequent to an open distal radius and ulna fracture injury was treated with the Acumed Total Wrist Fusion Plating System.

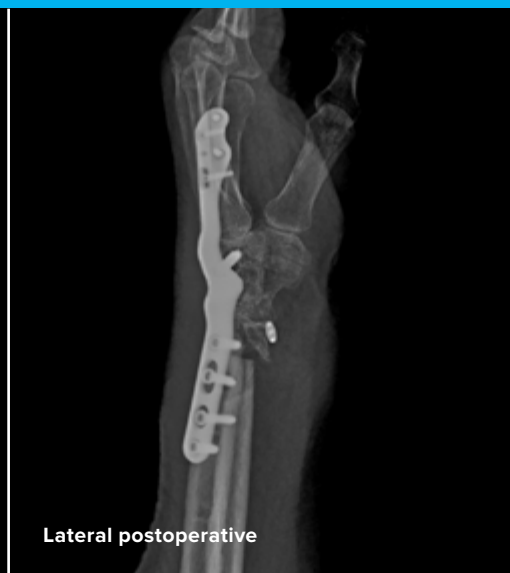
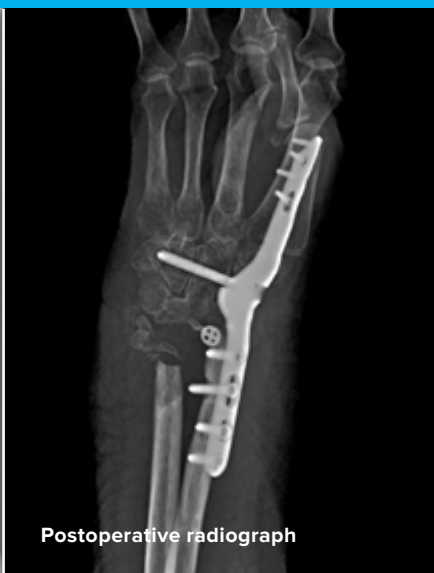
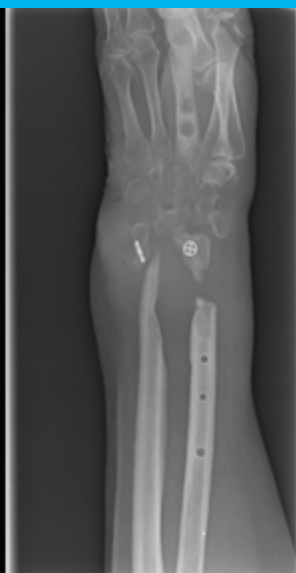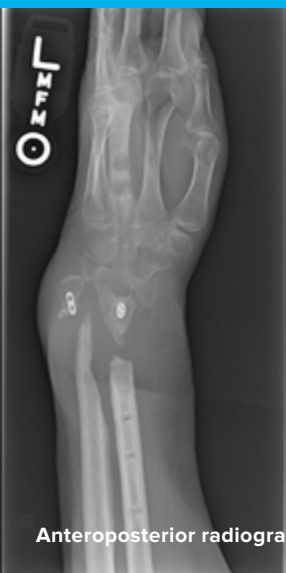Acumed® is a global leader of innovative orthopaedic and medical solutions.



We are dedicated to developing products, service methods, and approaches that improve patient care.

Case Study | William Geissler, MD

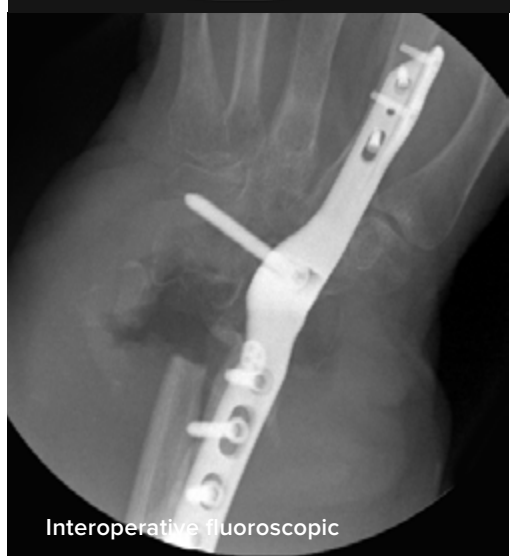
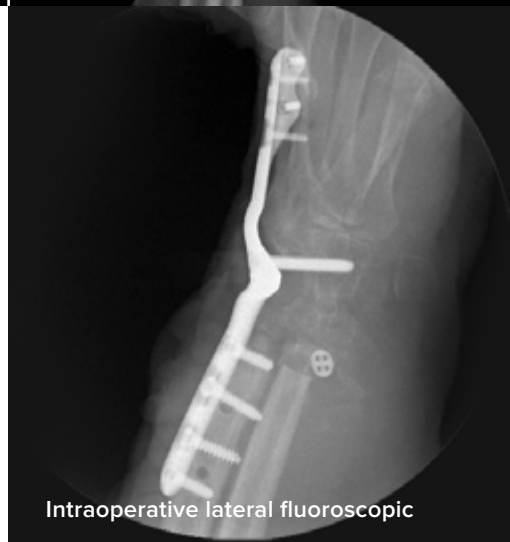
Wrist Salvage Procedure Using Second Metacarpal Plate Placement

Patient History

The patient is a 47-year-old male with a history of approximately 20 previous operations at an institution in other state. The patient's original injury was an open fracture of distal radius and ulna. The patient underwent previous irrigation and debridement as well open reduction and internal fixation. Eventually the plates were removed, as the patient had a continued chronic infection to both the distal radius and ulna. Following several debridements, the patient had remained free of any drainage. One of the patient's previous surgeries was an attempt at distal radioulnar joint stabilization.

The patient presented with severe pain to the distal radius and marked clinical deformity to the wrist. The patient had limited active motion to the wrist as well as limited supination. On physical examination, any range of motion to the wrist was quite painful. The previous incisions were not red hot or warm and there was no active drainage. The patient's lab work returned with a normal CRP and SED rate. Radiographs show a nonunion of both the distal radius and ulna. The patient had minimal remaining distal radius as well as a complete scapholunate dissociation. In addition, radiographs showed a suture device implanted in an attempt to stabilize the distal radial joint.



Treatment

The patient was brought to surgery for a wrist fusion to provide stability to the distal radioulnar joint. The extended dorsal approach was made to the wrist. The dorsal capsule was open with a radial based capsule flap exposing the carpus and remaining distal radius. At that point the articular cartilage was decorticated off the remaining distal radius and carpal bones.

The Acumed plate designed for second metacarpal placement was placed along the index metacarpal for the initial screw placement. A 2.3 mm screw was inserted into the slot of the distal screw hole in the plate. This compressed the plate down to the dorsal radial aspect of the index metacarpal. The remaining converging 2.3 mm screws were then placed into the metacarpal.

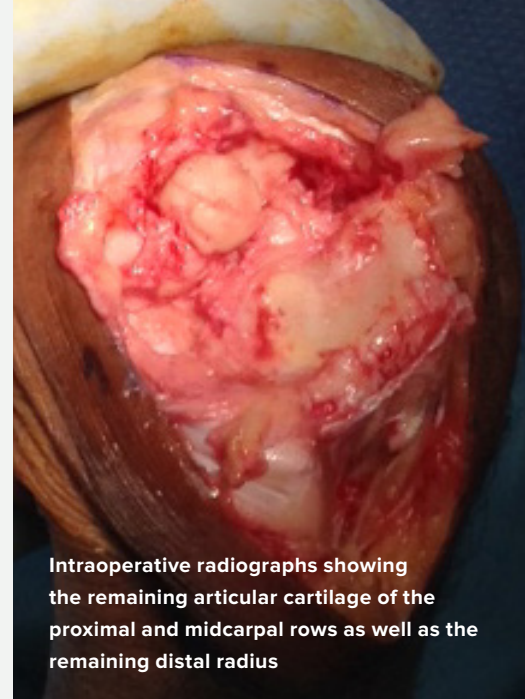Once the plate was secured to the index metacarpal, the plate and the carpus were reduced to the distal radius. The plate placement is just radial to the dorsal most prominent portion of the distal radius. This placement is intended to decrease as much extensor tendon irritation as possible. The first screw placed was a 3.5 mm nonlocking screw in the slot as the wrist was held reduced and compressed. A second 3.5 mm nonlocking screw was then placed in the offset screw hole to further compress the fusion site. The two remaining 3.5 mm locking screws were placed in the plate in the distal radius.

The last screw placed was the 3.5 mm locking screw in the carpal, which was aimed into the capitate at an oblique angle. It is important not to plunge when drilling this screw hole to avoid damage to the ulnar neurovascular bundle. The purpose of this screw is to decrease as much micromotion as possible between the index metacarpal and trapezoid joint.

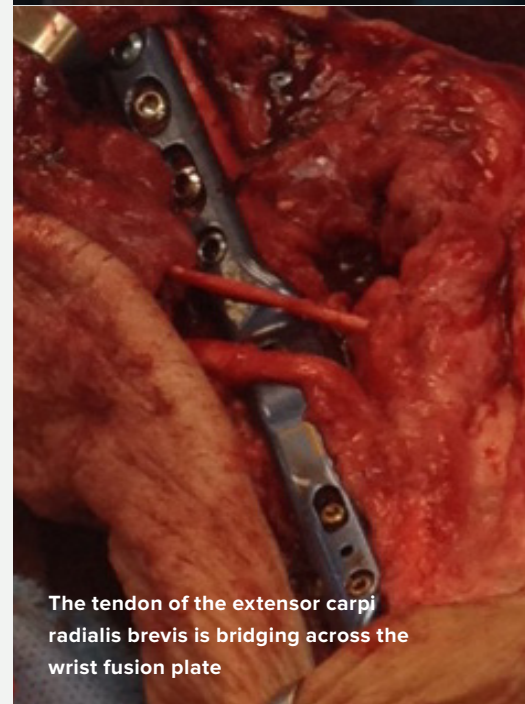
The dorsal capsule was closed over the plate in an attempt to prevent limited extensor tendon irritation. The second and fourth dorsal compartments were closed for stability to the extensor digitorum communis tendons. The extensor pollicis longus was left free and the skin was closed.

Postoperative Care

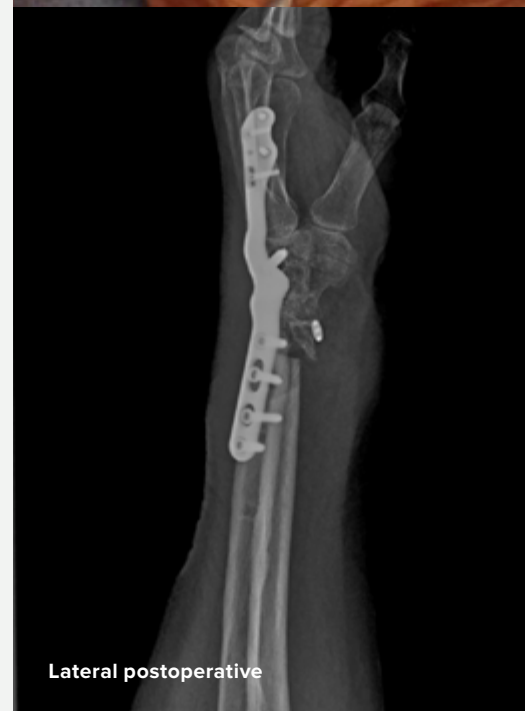Digital range of motion was started immediately postoperatively, and strengthening was started approximately two weeks out from surgery.



Intraoperative radiographs showing the remaining articular cartilage of the proximal and midcarpal rows as well as the remaining distal radius



The tendon of the extensor carpi radialis brevis is bridging across the wrist fusion plate



Lateral postoperative



HNW70-22-A

Effective: 2018/10

© 2018 Acumed® LLC

Acumed® Headquarters
5885 NE Cornelius Pass Road
Hillsboro, OR 97124
Office: 888.627.9957
Fax: 503.520.9618
www.acumed.net

These materials contain information about products that may or may not be available in any particular country or may be available under different trademarks in different countries. The products may be approved or cleared by governmental regulatory organizations for sale or use with different indications or restrictions in different countries. Products may not be approved for use in all countries. Nothing contained on these materials should be construed as a promotion or solicitation for any product or for the use of any product in a particular way which is not authorized under the laws and regulations of the country where the reader is located. Specific questions physicians may have about the availability and use of the products described on these materials should be directed to their particular authorized Acumed distributor. Specific questions patients may have about the use of the products described in these materials or the appropriateness for their own conditions should be directed to their own physician.

