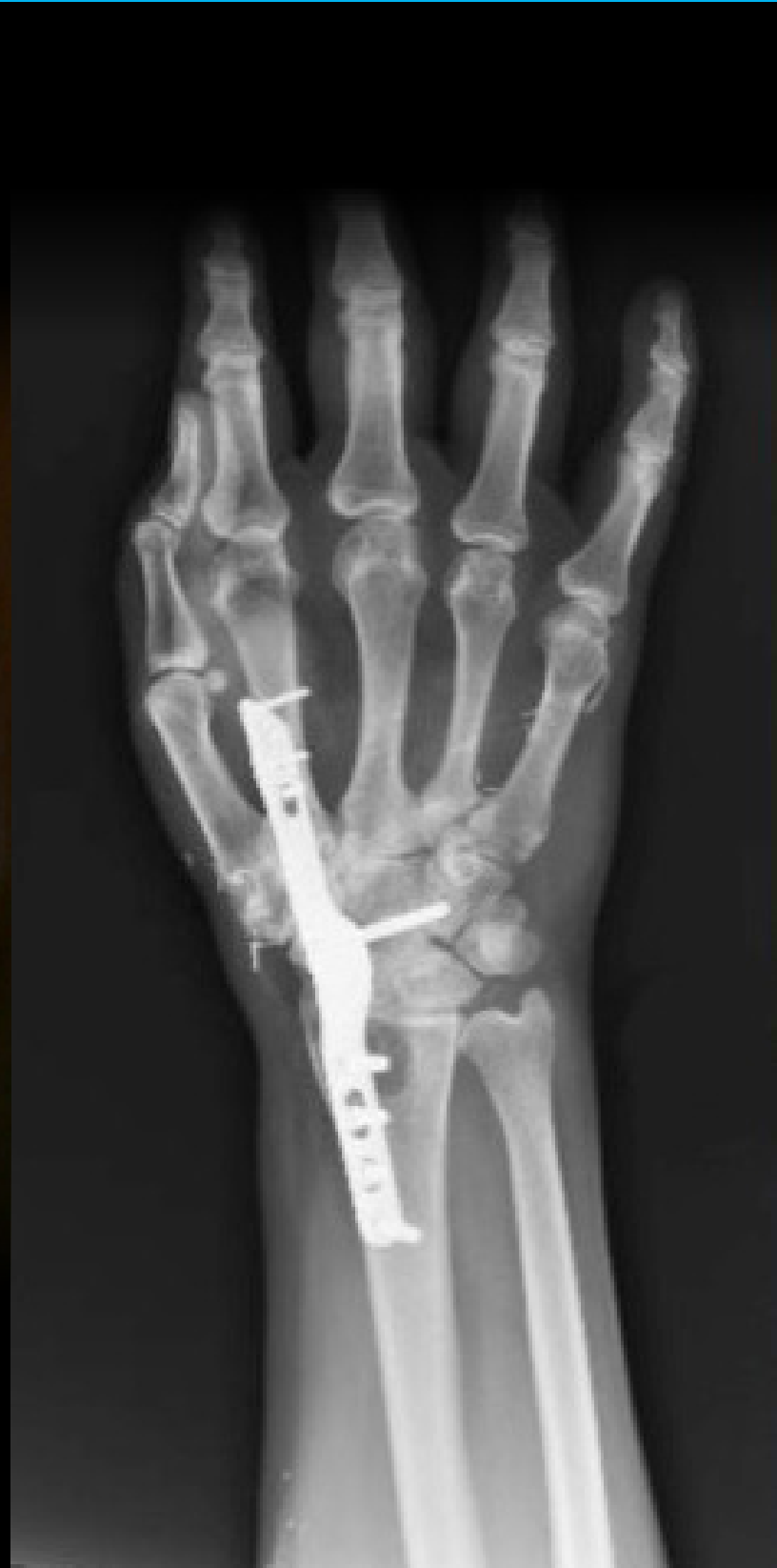
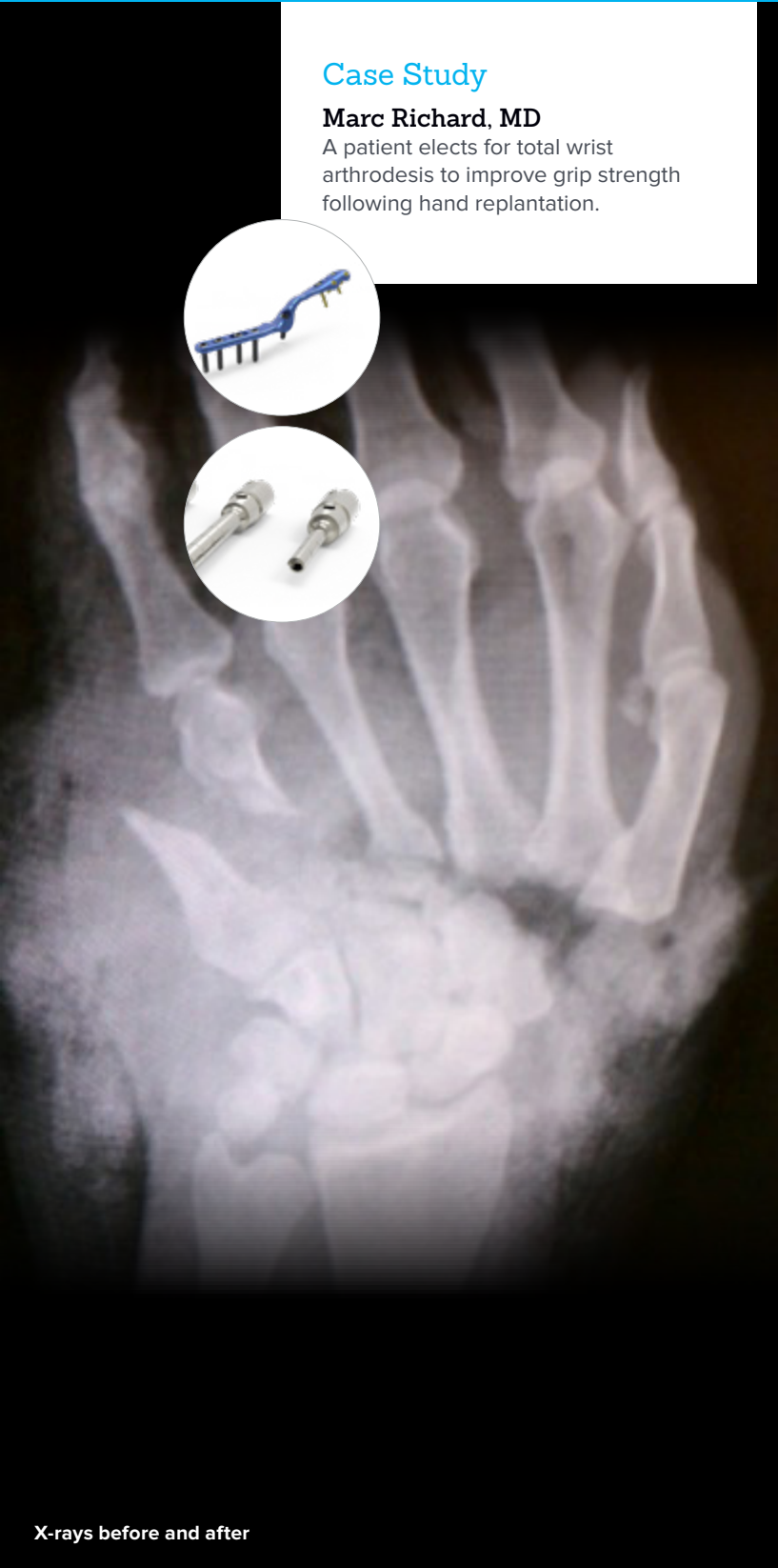
## Maximizing Wrist Function Through Total Wrist Arthrodesis

### Case Study

#### Marc Richard, MD

A patient elects for total wrist arthrodesis to improve grip strength following hand replantation.



Acumed® is a global leader of innovative orthopaedic and medical solutions.



We are dedicated to developing products, service methods, and approaches that improve patient care.

## Case Study | Marc Richard, MD

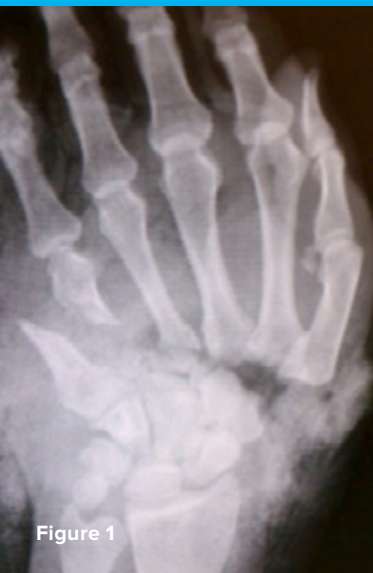

Figure 1

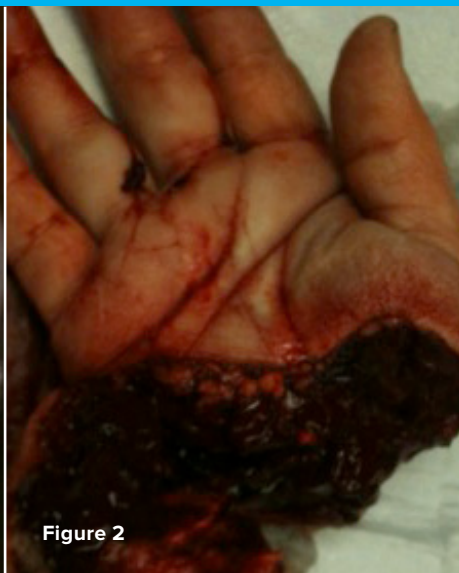

Figure 2

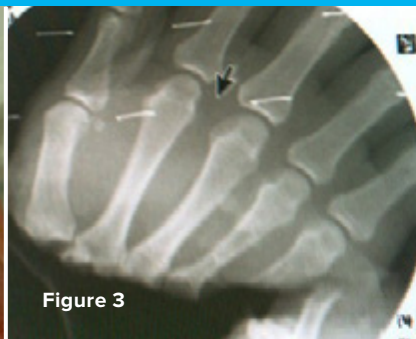

Figure 3

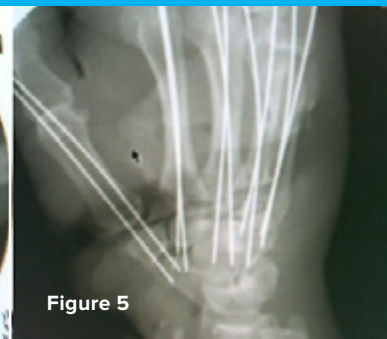

Figure 5

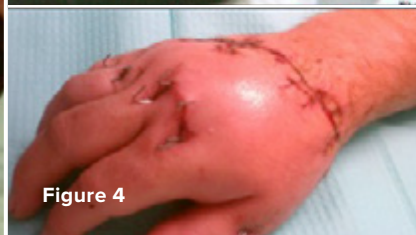

Figure 4

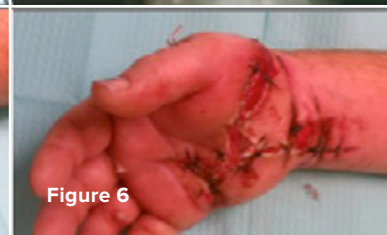

Figure 6

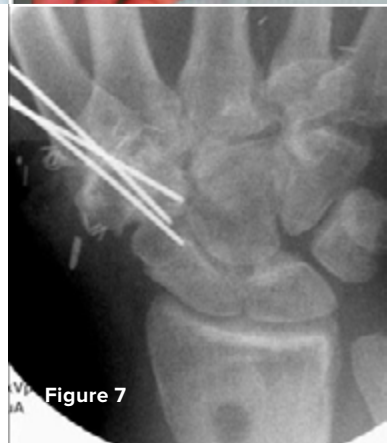

Figure 7

## Maximizing Wrist Function Through Total Wrist Arthrodesis

### Patient History

A 37-year-old right-hand dominant male butcher sustained a hand amputation in a meat chipper while at work (figures 1–3). He underwent a replantation of the hand (figures 4–6) and progressed well with hand therapy. He did not experience any meaningful motor recovery of the median nerve and was unable to oppose his thumb for pinch activities. At one year post-injury, he elected to undergo a CMC fusion of the thumb in opposition. This was successfully performed using Kirschner wires (Figure 7) and distal radius autograft harvested with the 7 mm Acumed Bone Graft Harvester. He was able to regain pinch strength (Figure 8), but he had weak wrist extension and his primary complaint was poor grip strength. His wrist fell into flexion during attempted grip, which limited his grip strength (Figure 9). His measured grip strength was four times greater while in a wrist splint in slight wrist extension than when he did not support his wrist. As a result, he was wearing his wrist splint continuously and desired definitive treatment to position his wrist in slight extension. He elected for a total wrist arthrodesis to position the wrist appropriately in order to maximize his grip strength.

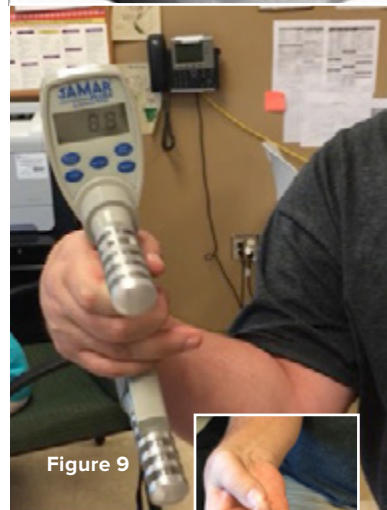


Figure 8



Figure 9

## Treatment

The patient was taken to the operating room for a radiocarpal arthrodesis. The patient also consented to autogenous bone grafting from the ipsilateral distal radius and iliac crest. The patient was placed supine on the operating table with a hand table attachment. The right upper extremity was prepped and draped in the usual sterile fashion. The surgical incision was then made longitudinally over the dorsum of the wrist from the distal radius to the index metacarpal.

Sharp dissection was carried down to the level of the extensor retinaculum. The extensor pollicis longus (EPL) tendon was identified and the third dorsal compartment was opened longitudinally. EPL was released from its compartment and transposed radially. The second and fourth compartments were elevated subperiosteally and retracted radially and ulnarly respectively. The dorsal capsule was then identified and a longitudinal capsulotomy was performed. The extensor carpi radialis longus tendon insertion was identified and noted to be damaged from the previous trauma. This was released to facilitate plate placement. A high-speed burr (Figure 10) was used to remove the articular cartilage of the radiocarpal, mid-carpal, and second carpometacarpal joints. The 7 mm Acumed Bone Graft Harvester (Figure 11) was used to collect autograft bone from the distal radius and iliac crest for the fusion sites.

The standard right Total Wrist Fusion plate was selected. Lister's tubercle was removed with a rongeur and the plate was placed on the dorsal aspect of the second metacarpal and the dorsoradial aspect of the distal radius. Care was taken to ensure that the plate was positioned as distally as possible so there was no gap present between the plate and the carpus (Figure 12). It was provisionally pinned with a 0.062 K-wire, and C-arm fluoroscopy was used to confirm appropriate plate placement.

Once proper plate position was confirmed, the distal aspect of the plate was fixed first using 2.3 mm MultiScrews. Attention was then turned to proximal plate fixation. While maximal manual compression was held, a 3.5 mm cortical screw was placed in the oblong hole. A second 3.5 mm cortical screw was then placed in the compression hole to maximize compression across the fusion site. The proximal fixation was then completed and a 3.5 mm locking screw was placed bicortically through the capitate and unicortically into the hamate (Figure 13).

C-arm fluoroscopy was again used to confirm appropriate alignment and position of the wrist and hardware (Figure 14). The capsule was closed over the plate, followed by the second and fourth compartments. The EPL tendon was left transposed superficial to the extensor.

## Postoperative Care

The patient was seen in clinic two weeks postoperatively for suture removal and wound check. At this time, he was placed into a short arm fiberglass cast and continued with digital range of motion. At six weeks postoperatively, radiographs demonstrated improved consolidation of his arthrodesis site and his immobilization was discontinued. He continued to work on digital range of motion and grip strength. At the time of his final follow-up, 18 months postoperatively, he was able to achieve 40 pounds of grip strength (figures 15–16) on his operative side and was pleased with the outcome.

## Discussion

Total wrist arthrodesis is performed for a variety of indications, including rheumatoid arthritis, post-traumatic arthritis, nerve injury, and spasticity. It is critical to position the wrist to maximize hand function. The Acumed Total Wrist Fusion Plating System allows for such positioning. When fusion to the second metacarpal is performed, the plate positions the wrist in 15° of wrist extension and 10° of ulnar deviation. These plates are side-specific and come in two lengths to allow for variability in patient size. Placement on the second metacarpal also minimizes plate contact with the digital extensors. The set has a neutral plate for the third metacarpal that is preferred in the setting of a proximal row carpectomy. Overall, the Total Wrist Fusion Plating System has a variety of options to help manage the array of indications for wrist arthrodesis.

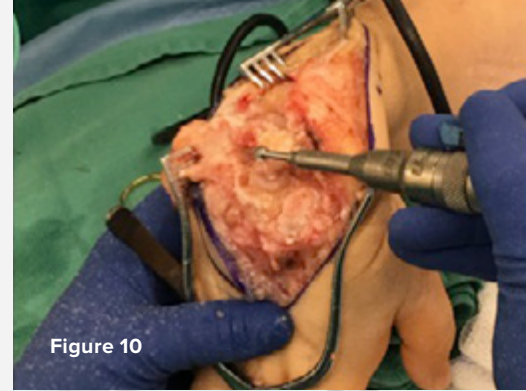


Figure 10

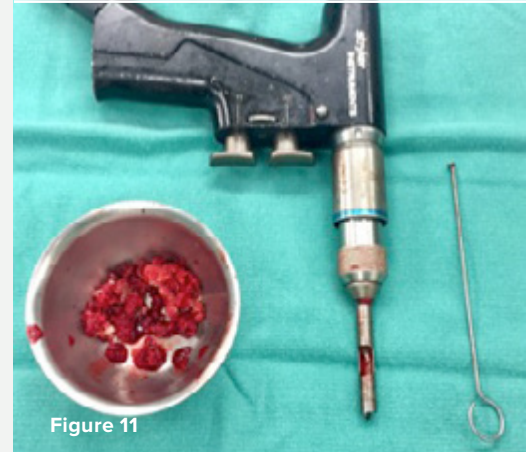


Figure 11

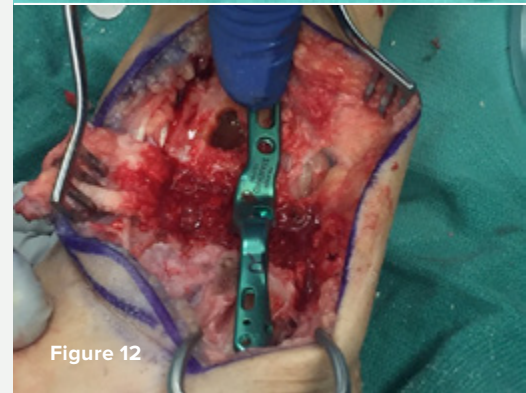


Figure 12

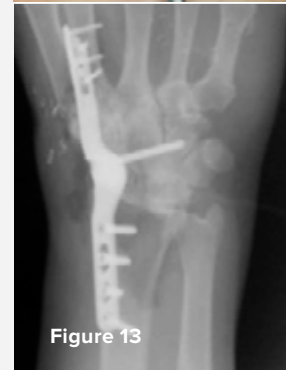

Figure 13

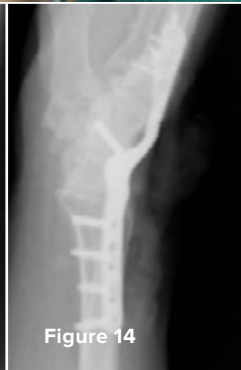

Figure 14

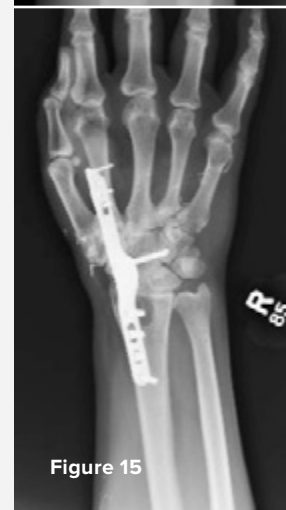

Figure 15



Figure 16



## **HNW70-19-A**

Effective: 2018/10

© 2018 Acumed® LLC

Acumed® Headquarters  
5885 NE Cornelius Pass Road  
Hillsboro, OR 97124  
Office: 888.627.9957  
Fax: 503.520.9618  
[www.acumed.net](http://www.acumed.net)

These materials contain information about products that may or may not be available in any particular country or may be available under different trademarks in different countries. The products may be approved or cleared by governmental regulatory organizations for sale or use with different indications or restrictions in different countries. Products may not be approved for use in all countries. Nothing contained on these materials should be construed as a promotion or solicitation for any product or for the use of any product in a particular way which is not authorized under the laws and regulations of the country where the reader is located. Specific questions physicians may have about the availability and use of the products described on these materials should be directed to their particular authorized Acumed distributor. Specific questions patients may have about the use of the products described in these materials or the appropriateness for their own conditions should be directed to their own physician.

